



## ECTOPARASITES IDENTIFICATION OF INDIGO RED FISH (*Oreochromis nilotica*) CULTIVATED IN THE CENTER OF THE FISH FRY (BBI) RANOMEETO

### AUTHORS INFO

Dedi Sunarto  
Postgraduate Student at Universitas Negeri Yogyakarta  
[dedisunarto61@gmail.com](mailto:dedisunarto61@gmail.com)  
+6282188124625

### ARTICLE INFO

ISSN: 0000-0000  
Vol. 1, No. 1, Desember 2019  
URL: <http://usnsj.com/index.php/biology>

© 2019 JBSE All rights reserved

### **Suggestion for the Citation and Bibliography**

*Citation in Text:*

Sunarto, D. (2019)

*Bibliography:* Sunarto, D. (2019). Ectoparasites Identification of Indigo Red Fish (*Oreochromis nilotica*) Cultivated in The Center of The Fish Fry (BBI) Ranomeeto. *Journal of Biological Science & Education*, 1 (1, Desember), 1-8.

### Abstract

Diseases caused by parasitic groups received less serious attention from the farmers because the disease is chronic morbidity and mortality rates and small. However, if observed further, parasitic diseases can lead to secondary infection by bacteria, viruses, and fungi that can cause death and high losses. This study aims to identify the types of ectoparasites red tilapia (*Oreochromis nilotica*) at Fish Seed Center (BBI) Ranomeeto, South Konawe. This type of method used was observational and sampling was done by using purposive sampling, ie taking into account the characteristics / criteria sample has been determined. These samples included 30 individuals of red tilapia fish taken from BBI Ranomeeto South Konawe. Observations ectoparasites done in Laboratory of Department of Biology at Halu Oleo University . From some of the samples examined *Trichodina* sp. found to infect the gills, skin and fins. *Ichthyophthyrus* sp. found on the skin. The dominant type of ectoparasites found is kind *Trichodina* sp. with a prevalence of 60% and *Ichthyophthyrus* sp. with a prevalence of 46.67%. with a prevalence of 60% and *Ichthyophthyrus* sp. with a prevalence of 46.67%. with a prevalence of 60% and *Ichthyophthyrus* sp. with a prevalence of 46.67%.

**Keywords:** Red Tilapia, Ectoparasites, and Organ Infections

### A. Introduction

Disease in fish is still one cause of death cause high losses in the cultivation process. Disease arises due to declining immune system in fish accompanied by a deterioration in the quality of water, making it easier for pathogens to infect fish. Disease-causing agents (pathogens) of fish can be derived from the class of parasites, bacteria, fungi and viruses. Parasites are organisms that need essential metabolites obtained and rely entirely on the host (Noble & Noble, 1989).

Tilapia (*Oreochromis nilotica*) is a species of fish that have high economic value and is an important commodity in the business world of freshwater fish. As one species of freshwater fish, tilapia has been developed as an export commodity in the form of whole fish or fillet. Hadiroseyani, (2009: 32) states that Tilapia gift is successful yielding varieties developed by the

International Center for Living Aquatic Resources Management (ICLARM). Gift name comes from the abbreviation Genetic Improvement of Farmed Tilapias, which is the result of crossing several varieties tilapia in several countries in the world. Until now, new varieties have been disseminated throughout the world, including Indonesia.

According Rahmi, (2012) stated that tilapia commodity potential to be developed as international and domestic market demand is quite high. But in the cultivation of freshwater fish there are obstacles that can inhibit the growth of cultured fish. One of the obstacles in the cultivation of freshwater fish, especially tilapia is the problem of diseases that often attack the fish. Among these diseases is an infectious disease caused by parasites such as protozoa, worms, viruses, bacteria, and fungi (Nurdiyanto and Sumartono, 2006: 136).

The success of a fish farming is determined by various factors, either external or internal factors. One factor that is very influential in the success of fish farming are diseases and parasites that attack the fish. The type and number of diseases and parasites that attack the fish can cause great harm to the fish farmers because it can lead to fish kills en masse. Disease that often infects farmed fish are generally derived from the class of fungi, bacteria, viruses, parasites and other invertebrate animals. The immune system in the fish's body is not fully developed so that the resistance of the fish's body to incoming pathogens is still weak (Purbomartono *et al*, 2007). Therefore, fish farming management effort required quality and free of infectious pathogens carried by Fish Seed Center (BBI) in each region. South Konawe Regency precisely in there Fish Seed Center (BBI) Ranomeeto, which provides seed requirements for fish farmers in the region Ranomeeto, South Konawe, namely BBI Ranomeeto.

Research on the identification of ectoparasites in BBI as a rare first to tackle the disease is still a bit to do. Research Abadiyyah (2010) reported that kinds of ectoparasites which attack fish carp water in (*Oshpronemus gouramy* Lac.) In BBI Randigundam Jember is *Ichthyophthyrus* sp., *Trichodina* sp., *Epistylis* sp., and *Argulus* sp. Results of another study also conducted by Cahyono *et al* (2006) found that fish seed Tawes (*Punctius javanicus*) in BBI Sidabowa, Banyumas and BBI Kutasari, Purbalingga infected ectoparasites kind *Trichodina* sp., *Ichthyophthyrus multifiliis*, *Myxobolus* sp., *Epistylis* sp., *Chilodenella* sp., *Vorticella* sp., and *Apistoma* sp. Therefore, Information on the type of ectoparasites that infect red tilapia fish in BBI Ranomeeto, South Konawe (*Oreochromis nilotica*).

## B. literature Review

### 1. Morphology Red Tilapia (*Oreochromis nilotica*)

Red tilapia (*Oreochromis nilotica*) brought to Indonesia in early 1981 by the Center for Freshwater Fisheries. This fish is probably the result of a cross between *Oreochromis mossambicus* or *Oreochromis niloticus* with *honorum*, *Oreochromis aiureus*, or *Oreochromis zillii* (Amri & Khairuman, 2003: 16).

In general, the shape of red tilapia long and slender, with large-sized scales. Her eyes are large and prominent. Lateral line is disconnected in the middle of the body and then continues. The number of scales on the lateral line as many as 34 pieces. The dorsal fin, pelvic fins and anal fins have soft fingers were hard and sharp like thorns. In addition, the visible pattern of vertical stripes on the tail fins were six and in the dorsal fin there are eight. Line with the same pattern (vertical line) is also on both sides of red tilapia with the number eight (Amri & Khairuman, 2003: 16).

Tilapia fish living in fresh waters such as rivers, lakes, reservoirs and wetlands, but because of the wide tolerance to salinity so that the fish can also live and breed in brackish water and sea water (Kordi, 2004: 20).

These fish can grow well at a temperature of 25-30°C, and during spawning requires temperatures of 22-27°C. The optimum pH value for breeding and partumbuhan tilapia is 7-8 (Rukmana, 1997: 20). Nila very response to intensive care, especially feeding factors in sufficient quantity and high quality. Nila has advantages such as relatively fast growth, easy to breed, and adaptability to high-growth environment (Santoso, 2000: 19).

### 2. Types of Ectoparasites on Red Tilapia

Parasites are one of the organisms that can cause death in fish. Ectoparasites are parasites that live on the skin, gills and the outer surface of the body of the fish. Nofyan *et al.* (2015) states that the parasite attacks impact on the appetite of fish, causing a decrease in the weight of fish. Parasites that infect fish will damage organs and result in disruption of the body's metabolic system in fish. It can affect the growth of fish and cause death.

Parasites have specific habitat in the body of its host. Based on the environment, the parasite divided into two ectoparasites, are parasites that live on the surface of the host body. strike the outside of the fish's body, for example in the gills, fins and skin, and endoparasites (parasites invade the inside of the body of the fish, such as the intestines, kidneys and liver) (Batam Fish Quarantine, 2007: 20). Several classes of parasites which are ectoparasites include ciliate, some flagellates, monogenea, copepod, isopod, branchiuran and leeches, whereas endoparasites is a parasite that is found on the host's internal organs. Group parasites that enter the group include digenea endoparasites, cestodes, nematodes, acantocephala, coccidia, microsporidia, and amoeba (Anshary, 2008: 14).

Some ectoparasites that attack the skin, fins and gills of fish, namely:

a. *Protozoa*

Protozoa are organisms unisellular (unicellular) are very small microscopic and have a complex structure that is used for movement, adhesion, and protection. Class and type of protozoan parasites that infect fish and shrimp are numerous, but the most common and often cause disturbances in fish and shrimp are: type of protozoan parasites are common in freshwater fish are: *Ichthyophthirius multifiliis*, *Trichodina* sp., *Trichodinella* sp., *Chilodonella* sp., *Tetrahymena* sp., *Ichthyobodo Necator*, *Piscinoodinium* sp., *Myxobolus* sp., *Henneguya* sp., and *Thelohanellus* sp. (Anshary, 2008: 26).

Protozoa are generally microscopic and consisting of a single cell. Has a composition, physiology and behavior are very complex (Noble and Noble, (1989) in Ohoiulun, 2002: 8). Protozoa generally grouped by the tool motion, Woo (1995) in Ohoiulun, (2002: 8), split over five phylum Protozoa, namely: Sarcomastigophora, Myxozoa, microspora, Ciliophora and Apicomplexa.

According to Davy and Chouinard (1983), in Ohoiulun, (2002: 8), a protozoan disease agents that are harmful for fish cultivation in Southeast Asia are: Myxosporea and Microsporea. Meanwhile, according to Landsberg (1989), in Ohoiulun (2002: 8), protozoan ectoparasites disease that often occurs is: *Ichthyophthiriasis*, *Costiasis*, *Tricodinasis* and *Chilodonellosis*.

The following are the types of protozoa that belong to the ectoparasites and endoparasites:

1) *Trichodina* sp.

*Trichodina* sp. is a pathogen of class Ciliate ectoparasites that attack freshwater fish. *Trichodina* sp. in small amounts does not cause serious impact but severe infections of this parasite will cause scars open to the outer body of fish (Untergasser, 1989 in Zheila, 2013: 3). These scars will be a vector carrying other more dangerous pathogens (Lom, 1995 in Zheila, 2013: 3).

According Afrianto and Liviawaty (1992) in Zheila, (2013: 3), a predilection *Trichodina* sp. is the surface of the body, fins and gills. Fish that tesorang *Trichodina* sp. characterized by the presence of white spots grayish and an increase in mucus production (Gusrina 2008 in Zheila, 2013: 3). The high intensity of *Trichodina* sp. caused by these parasites multiply quickly and pond water conditions that support for the life of these ectoparasites (Sachlan, 1972 in Zheila, 2013: 3). The high intensity of *Trichodina* sp. cause fish stress and mortality in the host. If the intensity *Trichodina* sp. in high amounts, will cause the fish looked pale, decreased appetite, and then will have a high mortality (Zheila, 2013: 3).

2) *Ichthyophthirius multifiliis*

*Ichthyophthirius multifiliis* causing white spot disease or Ich. Adult parasites have around and oval shape with a size of 0.5-1.0 mm, the whole body of ciliated and contains a horseshoe-shaped nucleus which can be seen in a microscope. These parasites multiply by splitting the binary. This parasite can infect the skin, gills and eyes on different types of fish both freshwater fish, brackish and sea that can cause skin damage and death (Yuliartati, 2011: 22).

*Ichthyophthirius multifiliis* infected fish causing the fish become lazy swim, visible white spots on the surface of the skin, gills and fins. If *Ichthyophthirius multifiliis* the gill then protozoa may damage the gills so that the process of gas exchange (oxygen, carbon dioxide, and ammonia) to be blocked (Kordi, (2004: 59).

3) *Chilodonella* sp.

*Chilodonella hexasticha* is a common parasite in fish reared in ponds (Landsberg, 1989 in Ohoiulun, 2002: 10). According to Kabata, 1985 in Ohoiulun, (2002: 10), that the infected fish become irritated, leaping from the water, it becomes weak and unresponsive. Gray slime covered skin. Gill severe damage seen with the occurrence of tissue hyperplasia.

4) *Oodinium* sp.

According to Axelrod and Schultz (1983), in Ohoiulun, (2002: 11), this parasite causes the velvet disease. Fish skin looks golden brown or yellowish. This parasite can be fatal for young

fish. According to Kabata, (1985) in Ohoiulun, (2002: 11), this parasite is epizootic in fish that live public waters, as well as an aquarium fish. Damage caused by adhesive organs penetration into the epithelial tissue of the host. These parasites also occur in gill, nasal cavity, oral cavity and eye.

#### b. *Trematodes (monogenea)*

*Monogenea* are external parasites in fish. *Monogenea* relatively simple life cycle; free-swimming ciliated larvae start an infection of the host fish. Although *monogenea* traditionally aligned with trematodes, some structural and chemical evidence shows that they are more closely related to the tapeworm (Campbell, 2008: 248).

Group *monogenea* many parasites cause problems in fish farming there are at least 4 family, namely *Microbothriidae*, *Capsalidae*, *Dactylogyridae* (*Dactylogyrus* spp., *Pseudodactylogyrus*), and *Gyrodactylidae* (*Gyrodactylus* spp.). Among parasite introductions have led to problems in its new place is *Gyrodactylus salaris* and *Pseudodactylogyrus* (Anshary, 2008: 53). Species of the class *monogenea* most commonly occurring in freshwater fish is *Dactylogyrus* sp. and *Gyrodactylus* sp.

##### 1) *Dactylogyrus* sp.

*Dactylogyrus* (common name: Gill Fluke) is monogenea which lay eggs and have two pairs of anchors. In the body there is the posterior Haptor. Haptornya kutikular lacks structure and has a pair of hooks with a single line kutikular, has 16 main hook, a pair of very small hooks. *Dactylogyrus* sp. has ophishaptor (posterior sucker) with 1-2 pairs of large hooks and 14 hooks marginal contained in the posterior. The head has four lobes with two pairs of eyes are located in the pharynx (Yudhie 2010 in Yuliartati 2011: 23).

Attacked fish *Dactylogyrus* sp. will usually be thin, swim jerky, gill cover can not be covered with broken perfect because their gills and skin of fish is not clear anymore. Symptoms of infection *Dactylogyrus* sp. in fish, among others: increased respiratory fish, excess mucus production, which affected the gills change color to pale and whitish. *Dactylogyrus* sp. often attack fish in high density ponds and fish are less eat more often attacked than the adequacy of these parasites feed. This includes parasitic worm parasites that need to be considered, because it can damage the gill filaments, and are relatively more difficult to control. This disease is very dangerous because it usually attacks the fish along with other parasites (Sachlan, 1952 in Hand, 2013: 12).

##### 2) *Gyrodactylus* sp.

*Gyrodactylus* sp. also round and long body. Animal measuring 0.2-0.5 mm. At the anterior end there are two lobes. Each lobe has a head and has a two-pronged intestine where the edges are not united. This parasite does not have vitelaria or united with the ovary. Cycle *Gyrodactylus* sp. from larva to become adult takes about 60 hours. It happened at a temperature of 25-27 ° C. Bio-ecology of the pathogen include ectoparasites, are obligate parasitic and reproduce by birth, has no eye point, and at the head end there are 2 pieces bulge. Transmission occurs horizontally and infect all species of freshwater fish in the seed stage and covers the entire surface of the target organ of the fish's body, especially the skin and fins (Hoffan, 1967 Hand, 2013: 13).

#### c. *Crustaceans*

One type of crustacean are ectoparasites is *Lernea* sp. which is a phylum Arthropoda, Entomostraea subclass, the order Copepoda, family Lemaideae, *Lernea* genus, species *Lernea* sp. Kordi (2004: 61) explains that the parasite *Lernea* sp. tends to resemble a needle stuck in the fish's body, so often called mite needle.

### C. Methodology

#### 1. Research Design

This research is a qualitative research, which identifies the types of ectoparasites contained in the red tilapia (*Oreochromis nilotica*), conducted descriptively by comparing images parasite that is found using Foundations Of Parasitology book by Larry S. Roberts and John Janovy, JR and Parasites of North American Freshwater Fishes by GL Hoffman.

#### 2. Instruments

The tools used in this study include a bar, scales, razor blade / scissors, tweezers, a petri dish, a glass slide, cover glass, microscope / magnifier, and a camera. The materials digunakan in this study is a red tilapia fish (*Oreochromis niloticus*), and water / distilled water.

### 3. Technique of Data Analysis

The sample data parasite that is found in the organs (fins, skin and gills) of red tilapia (*Oreochromis niloticus*) were analyzed and explained descriptively. Then calculated the prevalence and the average by using the formula (Ulhaq, 2012: 96).

#### 1. Prevalence

$$P = \frac{N}{n} \times 100$$

by:

P = Prevalence (100)

N = number of samples are attacked (tail)

n = number of samples observed (tail)

#### 2. Average

$$I = \frac{P}{N} \text{ (Ind / tail)}$$

by:

I = average parasite attack (individual / head)

P = Number of parasites found (people)

N = number of samples to be infected (tail).

## D. Results and Discussion

### 1. Results

#### a. Infestations Ectoparasites In Red Tilapia (*Oreochromis niloticus*)

Examination results ectoparasites on red tilapia (*Oreochromis niloticus*) can be seen in Table 2.

**Table 1. Results of Examination Ectoparasites on Red Tilapia (*Oreochromis niloticus*)**

No.	Type Parasites	Size	Number of Parasites			
			Skin	Fin	Gill	Total
1.	<i>Trichodina</i> sp.	Small	23	7	5	35
		Medium	35	11	4	50
		Big	11	5	-	16
Total			69	23	9	101
2.	<i>Ichthyophthyrus</i> sp.	Small	25	-	-	25
		Medium	19	-	-	19
		Big	14	-	-	14
Total			58	-	-	58
Total number			127	23	9	159

Based on Table 1 the results of ectoparasites on organ red tilapia (*Oreochromis niloticus*) shows that of the three organs studied were the skin, fins, and gills were found two species of ectoparasites that *Trichodina* sp. and *Ichthyophthyrus* sp. Differences location terserangnya organ ectoparasites on tilapia that has been studied is *Trichodina* sp. which is found on the skin, fins, and gills, *Ichthyophthyrus* sp. which is found only on the skin.

The prevalence of parasites on the examination results of red tilapia (*Oreochromis nilotica*) can be seen in Table 2.

**Table 2. Prevalence of Infection Ectoparasites In Red Tilapia (*Oreochromis nilotica*)**

No.	Type of Parasite	Prevalence (%)		
		Small	Medium	Big
1.	<i>Trichodina</i> sp.	60	80	40
2.	<i>Ichthyophthyrus</i> sp.	50	50	40

Based on Table 2 that the prevalence of parasites BBI Ranomeeto. namely *Trichodina* sp. 60% and *Ichthyophthyrus* sp. 46.67%.

The average of the results of the examination of parasites in the red tilapia (*Oreochromis nilotica*) can be seen in Table 3.

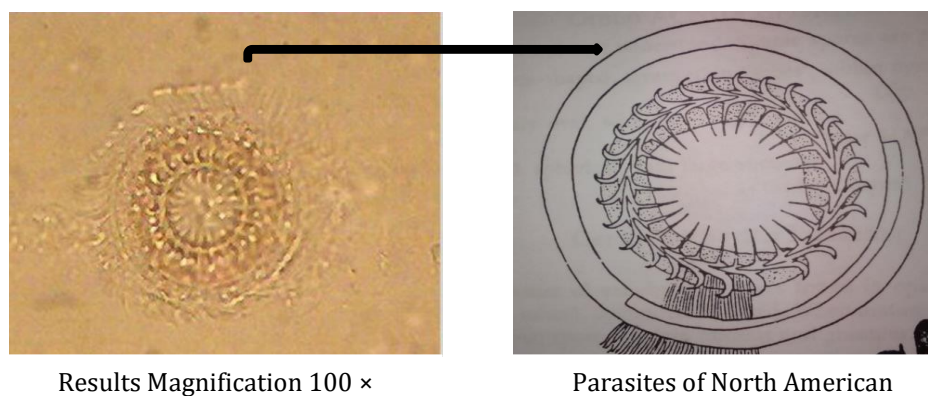
**Table 3. Average Parasite Examination At Red Tilapia (*Oreochromis nilotica*)**

No.	Parasites	Mean (individual / head)		
		Small	Medium	Big
1.	<i>Trichodina</i> sp.	5.83	6.25	4
2.	<i>Ichthyophthirius</i> sp.	5	3.8	3.5
3.	<i>Gyrodactylus</i> sp.	-	-	-

Based on Table 3 shows the parasite in fish samples attack in BBI Ranomeeto, *Trichodina* sp. infect fish small size of 5.83 people / head, medium-sized fish of 6.25 individual / head, while large-sized fish by 4 individual / head. For this type of *Ichthyophthirius* sp. infect fish that are small by 5 individual / head, medium sized fish as much as 3.8 individuals / head, while large-sized fish as much as 3.5 individuals / tail.

1) *Type Ectoparasites In Red Tilapia (Oreochromis niloticus)*

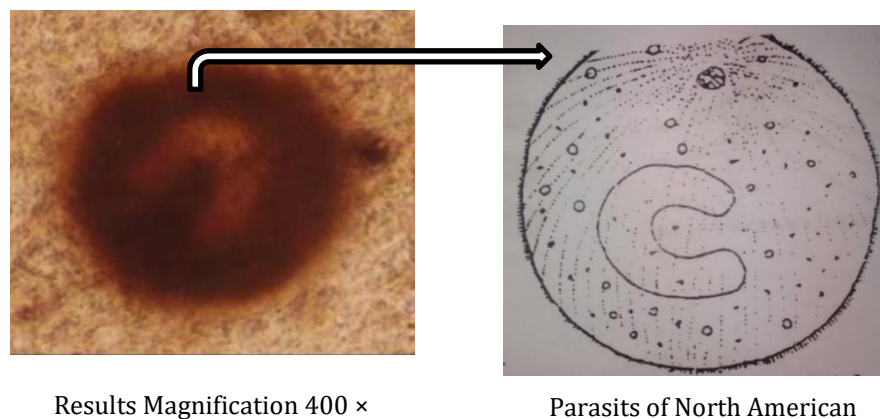
Type ectoparasites that infect red tilapia (*Oreochromis niloticus*) is *Trichodina* sp., and *Ichthyophthirius* sp. The results of the morphological study of ectoparasites *Trichodina* sp., Can be seen in Figure 1.



**Figure 1. Morphology *Trichodina* sp.**

Morphological features of ectoparasites *Trichodina* sp. found in tilapia is  $\pm$  50nm-sized parasites shaped like a flat plate or round, and while swimming looks like a flying saucer. On the disk platters are organelles called dentikel ring (ring dentikel) as a means of engaging and cilia around his body. This parasite is found in the gills and body surface (Anshary, 2008: 48).

The results of the morphological study of ectoparasites *Ichthyophthirius* sp can be seen in Figure 2.



**Figure 2. Morphology *Ichthyophthirius* sp.**

Morphological features of ectoparasites *Ichthyophthirius* sp. found in tilapia is having an oval-shaped body, elongated (34-45  $\mu$ m) and the whole body was covered with cilia. *Ichthyophthirius* sp. is an obligate parasite, swim actively looking for a host. *Ichthyophthirius*

sp. Adults are oval (0.5-1  $\mu\text{m}$ ) buried himself under the skin mucus, fins, and gills and look like white spots with the naked eye (Hoffman, 1967: 37).

#### b. Discussion

Based on the research discovered two types of ectoparasites that infect tilapia (*Oreochromis nilotica*) is *Trichodina* sp. and *Ichthyophthirius* sp. *Trichodina* sp. is one of the parasites known to infect farmed fish, especially on the skin and gills and is commonly found in freshwater fish seed (Noble, 2010). The organism can be attached by adhesion (pressure from outside), and feed on mucus or fluid in the cells contained in the epidermis. This parasite can not live outside any host. Adherence *Trichodina* sp., In fish body is actually just a place adhesion (substrate), while the parasite is taking organic particles and bacteria attached on the skin of the fish. But because of the strong adhesion and the presence of hooks on the disc, resulting in often arise itching of the fish so that the fish will rub up against the bottom of the pool or by the pool, so it can cause injury (Mahatma *et al*, 2012).

Parasitic infections *Trichodina* sp. The most dangerous is the result of the movement, so that each individual parasites will spread and affected a wide area. Infected fish will show a habit of rubbing against the wall and show an abnormal body color. The skin becomes irritated, hyperplasia, degeneration and necrosis of epithelial cells appeared hand in hand with the proliferation of mucous cells (Kabata, 1985).

Parasitic infections *Trichodina* sp. The most dangerous is the result of the movement, so that each individual parasites will spread and affected a wide area. Infected fish will show a habit of rubbing against the wall and show an abnormal body color. The skin becomes irritated, hyperplasia, degeneration and necrosis of epithelial cells appeared hand in hand with the proliferation of mucous cells (Kabata, 1985 in Hand, 2013: 13).

Other organisms found in this research that *Ichthyophthirius* sp. *Ichthyophthirius* sp. has infected red tilapia in BBI Ranomeeto with infection rate of 46.67%. The high rate of infection of *Ichthyophthirius* sp. the fish is suspected because of the rainy season. In accordance with the statement Afrianto and Liviawati, (1992: 64) that the attack *Ichthyophthirius* sp. generally occurs in the rainy season (20-24°C), Whereas, in the dry season it is only sporadic.

The results showed that the pool generally has a fairly high density, leading to high-level contact between the fish, thus speeding up the spread of parasites in the pond. According to (Kabata, 1985 in Noble, 2010: 7) that *Ichthyophthirius* sp. is one member of protozoa frequently attack and cause disease in fish. These protozoa have a small size, diameter 50-1000 $\mu\text{m}$ . This organism causes the disease known as white spot or Ich, because of the high infection rates cause white spots on the body surface. Afrianto & Liviawati (1992: 65), adding that his favorite part of the body is the external part, especially the mucous layer of the skin, fins, and gills. If it is attacking the gills, these organisms will damage the function of the gills,

#### E. Conclusion

Based on the above research ectoparasites that infect red tilapia (*Oreochromis niloticus*) in BBI Ranomeeto, South Konawe consists of two genus kinds *Trichodina* sp. and *Ichthyophthirius* sp. each of which is found on the skin, fins, and gills. Further research is needed to prevent the spread of parasites in healthy fish in BBI Ranomeeto, South Konawe.

#### F. References

- Amri, Khairul, & Khairuman. (2003). *Budidaya Ikan Nila Secara Intensif*. Jakarta: PT. Agro Media Pustaka.
- Anshary, H. (2008). *Modul Pembelajaran Berbasis Student Center Learning (SCL) Mata Kuliah Parasitologi Ikan*. Makassar: Universitas Hasanuddin.
- Balai Karantina Ikan Batam. (2007). *Laporan Pemantauan HPI/HPIK Tahun 2007*. Batam: Balai Karantina Ikan Batam.
- Campbell, N.A. (2008). *Biologi Edisi Kedelapan Jilid 2*. Jakarta: Erlangga.
- Hadiroseyani, Y, Harti, L.S., & Nuryati, S. (2009). Pengendalian Infestasi Monogenea Ektoparasit Benih Ikan Nila Gift (*Oreochromis sp.*) dengan Penambahan Garam. *Jurnal Akuakultur Indonesia*. 8 (2).
- Kabata, Z. (1985). *Parasites and Disease of Fish Cultured in The Tropics*. Philadelphia: International Development Resreach Council.
- Kordi, M.G.H. (2004). *Penanggulangan Hama dan Penyakit Ikan*. Jakarta: PT. Bina Adiaksara & PT. Rineka Cipta.

- Mahatma, Radit, Yusfiati, Elvira, R, & Titrawani. (2012). *Beberapa Aspek Biologi Ikan Baung (Mystus nemurus C.V) Dari Perairan Sungai Siak*. Riau: Laporan Penelitian Berbasis Lab. Fakultas Matematika dan Ilmu Pengatahuan Alam. Universitas Riau.
- Mulia, D.S. (2010). *Tingkat Infeksi Ektoparasit Protozoa pada Benih Ikan Nila (Oreochromis niloticus) di Balai Benih Ikan (BBI) Pandak dan Sidabowa, Kabupaten Banyumas*. Purwokerto: Skripsi Universitas Muhammadiyah Purwokerto, Tidak dipublikasikan.
- Nurdiyanto & Sumartono. (2006). *Model Distribusi Monogenea pada Ikan Nila (Oreochromis nilotica) di Daerah Istimewa Yogyakarta*. Yogyakarta: Skripsi Universitas Gadjah Mada, Tidak dipublikasikan.
- Ohoiulun, I. (2002). *Inventarisasi Parasit Pada Ikan Cupang (Betta splendens Regan), Ikan Gapi (Poecilia reticulate Peter) dan Ikan Rainbow (Melanotaenia macculochi Ogilby) di Daerah Jakarta Barat, DKI Jakarta*. Bogor: Institut Pertanian Bogor.
- Rahmi. (2012). Identifikasi Ektoparasit pada Ikan Nila (Oreochromis Niloticus) yang Dibudidayakan pada Tambak Kabupaten Maros. *Jurnal Ilmu Perikanan*. 1(1): 19-23.
- Santoso, H.B. (2000). *Usaha Ikan di Lahan Pekarangan*. Yogyakarta: Kanius.
- Ulhaq, F.M., Kismiyanti, Kusdawarti, R. (2012). Studi Identifikasi dan Prevalensi Endoparasit Pada Saluran Pencernaan Ikan Kerapu Tikus (Cromileptes activeles) Di Keramba Jaring Apung Unit Pengelola Budidaya Laut Situbondo Jawa Timur. *Jurnal Ilmiah Perikanan dan Ilmu Kelautan*. 4(1). Fakultas Perikanan dan Kelautan. Universitas Airlangga.
- Yuliartati, E. (2011). *Tingkat Serangan Ektoparasit Pada Ikan Patin (Pangasius djambal) Pada Beberapa Pembudidayaan Ikan Di Kota Makassar*. Makassar: Skripsi Universitas Hasanudin, Tidak dipublikasikan.
- Zheila, P. R. N. (2013). *Prevalensi dan Intensitas Trichodina sp. Pada Benih Ikan Nila (Oreochromis niloticus) di Desa Tambakrejo, Kecamatan Pacitan, Kabupaten Pacitan*. Surabaya: Skripsi Institut Teknologi Sepuluh November, Tidak dipublikasikan.